

# Precocious Puberty

Dan Hagger  
Paediatric Consultant

# Aims/Objectives

- By the end of this session, you should be able to...
- Describe what Precocious Puberty is
- Explain the physiology of normal onset of puberty and its clinical picture
- Recognize the differences between the two forms of Precocious Puberty
- Categorize the different causes Precocious Puberty
- Discuss the important aspects of the history and examination of a child with Precocious Puberty
- Demonstrate the investigations that are needed to aid diagnosis of Precocious Puberty

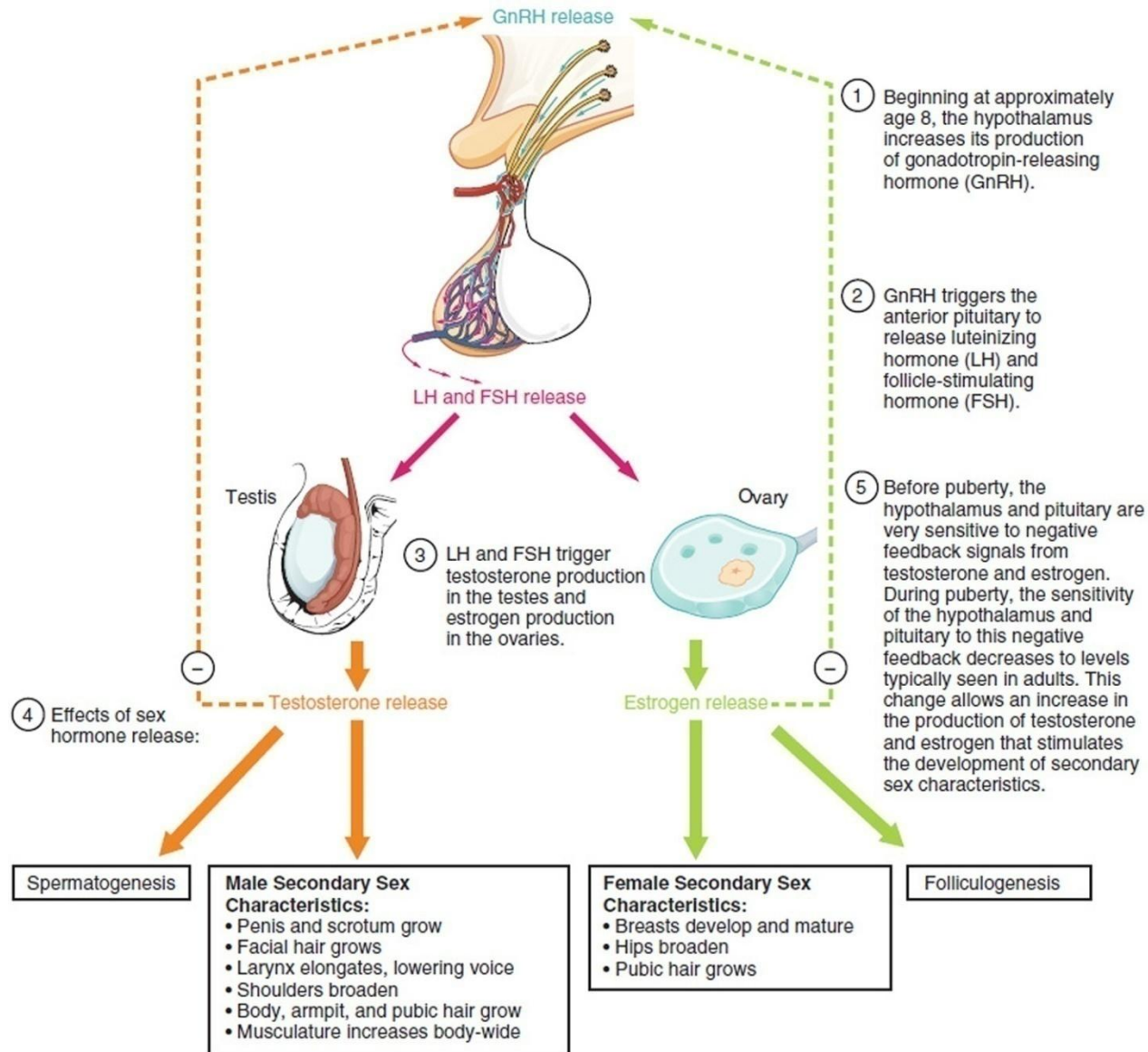
Describe What Precocious  
Puberty Is

# What is it?

- Precocious puberty should be considered when secondary sexual characteristics appear:
- Before 8 years of age in girls
- Before 9 years of age in boys

Explain The Physiology of Normal  
Onset of Puberty and Its Clinical  
Picture


# Physiology – Normal Puberty



# Physiology - Normal pubertal development

- Boys –
- First sign of puberty is increase in the size of the testes
- Testicular size is documented as a measurement of testicular volume using the Prader orchidometer
- Volume of 4 mL defines the onset of puberty
- Followed by penile and scrotal changes
- Axillary hair/voice/increase in growth velocity only occur in mid to late puberty
- Growth spurt at Tanner Stage 3-4
- Facial hair does not appear until late puberty


# Physiology - Normal pubertal development



# Physiology - Normal pubertal development

- Girls -
- First sign of puberty is breast development
- Pubic and axillary hair, acne, and body odour develop as a result of androgens secreted from the adrenal gland
- Peak growth spurt occurs in Tanner stage 2-3
- Menarche occurs at Tanner stage 4 breast development

# Physiology - Normal pubertal development

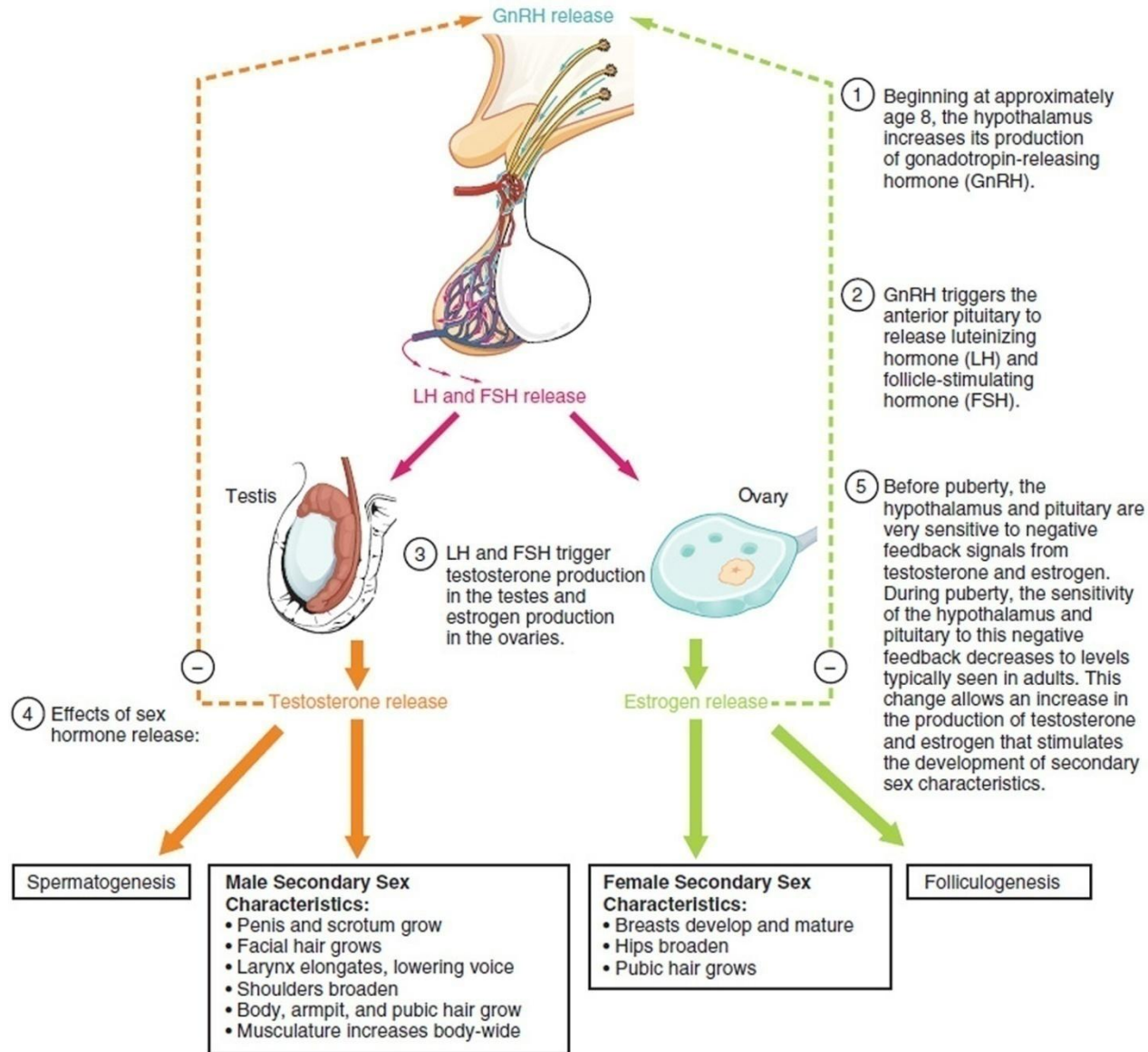


# Recognize The Differences Between The Two Forms of Precocious Puberty

# Physiology – Precocious Puberty

- Two forms exist:
- Gonadotropin-**dependent** precocious puberty –
- Due to premature activation of the hypothalamo-pituitary-gonadal axis – i.e. central – follows normal puberty pattern
- Gonadotropin-**independent** precocious puberty –
- Due to premature activation of the ovaries, testes, or adrenal glands (independent of gonadotropin secretion) – i.e. does not follow normal pattern

# Physiology – Normal Puberty



# Categorize The Different Causes Precocious Puberty

# Causes - Gonadotropin-dependent precocious puberty:

- Idiopathic: most common cause in females (90%) but rare in males (less than 10%)
- CNS - Brain neoplasms – e.g. neurofibromatosis, craniopharyngiomas, hydrocephalus, cerebral palsy, post-infection (meningitis/ encephalitis)
- CNS - Midline brain abnormalities – e.g. septo-optic dysplasia/holoprosencephaly
- CNS - Post-traumatic head injury/cranial radiation therapy
- Genetic - Neurofibromatosis type 1 and Sturge-Weber and tuberous sclerosis

# Causes - Gonadotropin-independent precocious puberty

- Ovarian - Follicular cysts, granulosa cell tumors, Leydig cell tumors, and gonadoblastoma
- Testicular - Leydig cell tumors and a defect of luteinizing hormone (LH) receptor function
- Genetic - McCune-Albright syndrome
- Adrenal – 21(and 11)-hydroxylase deficiency CAH (Congenital Adrenal Hyperplasia)
- Adrenal - Cushing syndrome and adrenal virilizing tumors

Discuss The Important Aspects of  
The History and Examination of a  
Child With Precocious Puberty

# History

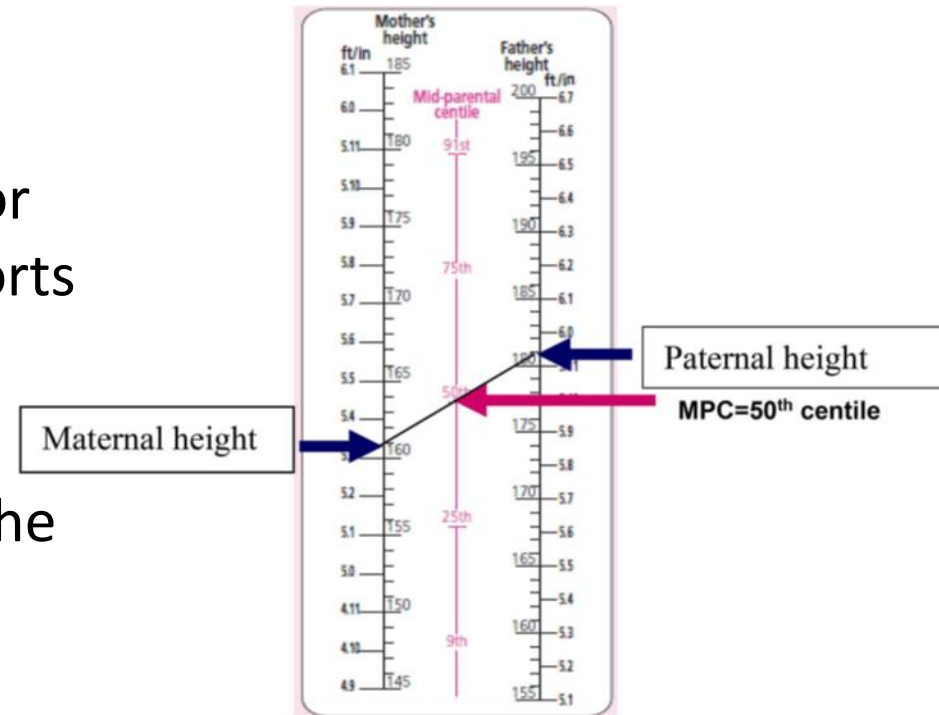
- Should be directed dependent on whether puberty is consonant or disconsonant
- i.e. whether the pattern of endocrine change is the same as in normal puberty or not
- Which signs of puberty (eg, pubic hair, acceleration in height, acne, greasy hair, body odour, breast and genital development) the child or their parents have noticed, and in what order?

# History


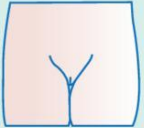


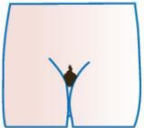
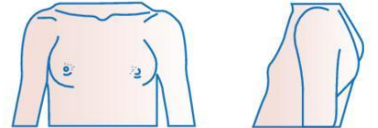

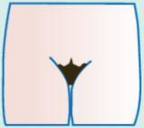
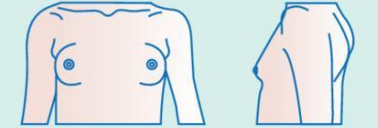


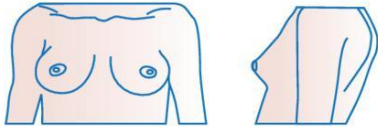



- When did they first notice the changes and how rapidly have they progressed?
- Very rapid progression of physical changes is more likely to result from a serious cause of GIPP, such as gonadal tumours or cysts
- Have they noticed any other symptoms?
- Symptoms such as headache, polyuria or polydipsia, or impairments in vision, could indicate serious underlying pathologies such as brain neoplasms
- Greasy skin and hair, acne, body odour, mood swings = evidence of excess steroid production

# Examination

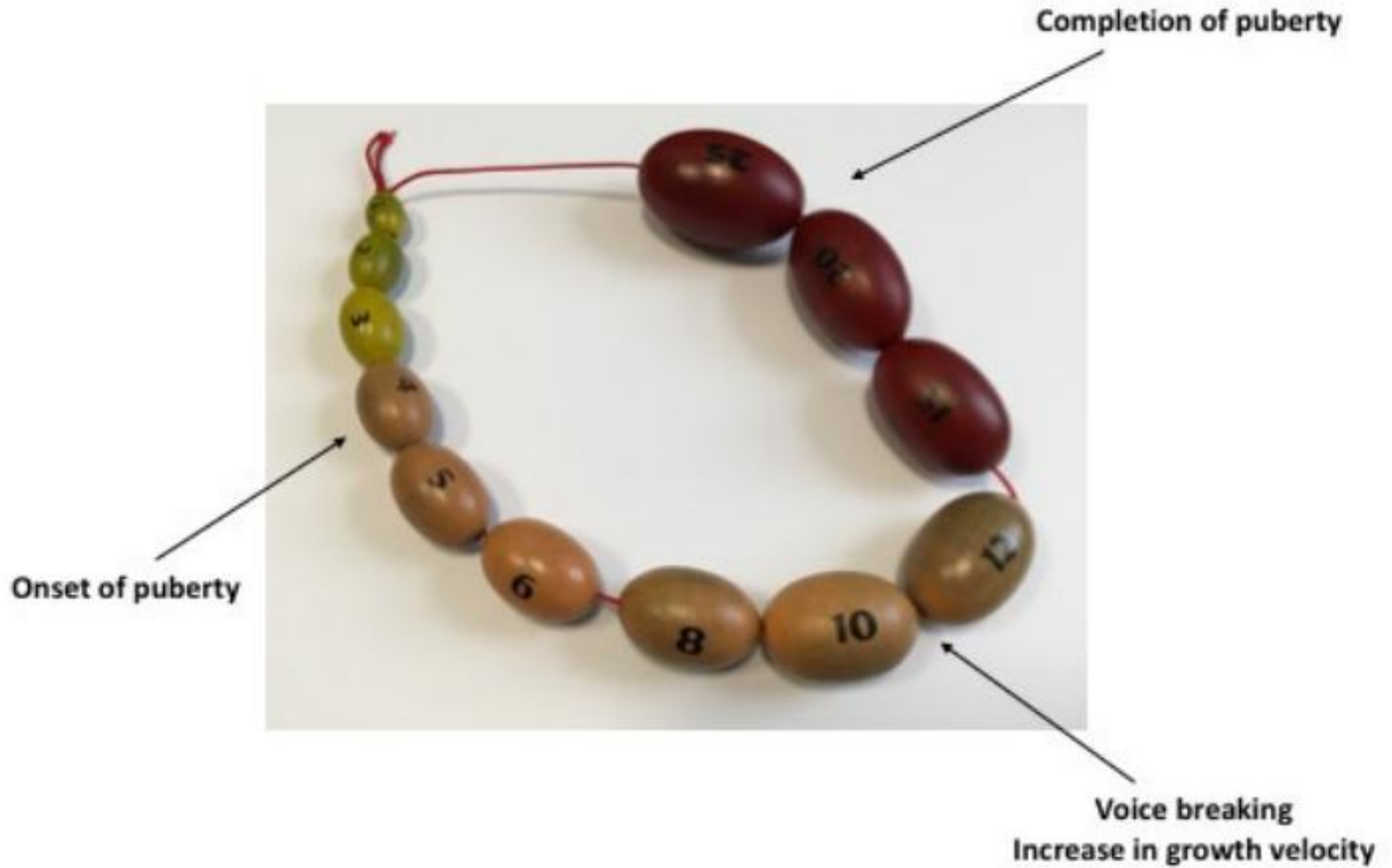
- Plot growth (ideally serial measurements)
- Height increasing across one or more full centile spaces supports a diagnosis of precocious puberty
- Compare height centile with the mid-parental centile
- Plot parents' height and join these two points with a straight line. The MPC is determined by the centile that intersects the centre of this line



# Examination

Tanner stage	Male genital appearance	Male genital description	Female pubic hair appearance	Pubic hair description	Breast appearance	Breast description
1		Testicular volume <3ml		No pubic hair		Elevation of papilla only
2		Testicular volume <3ml, change in texture to scrotal skin		Sparse growth chiefly along the labia/base of penis		Breast bud stage
3		Increase in size of penis with further testicular enlargement		Darker, coarser, more curled hair		Enlargement of breast and areola
4		Further enlargement of penis and testicles with development of glans penis		Adult type hair over a smaller area		Projection of the areola and papilla
5		Adult size and shape		Spread to the medial surface of the thighs		Recession of the areola to the contour of the breast, projection of papilla only

# Examination - Boys



# Examination - Boys

- Penile/testicular development in boys before 9 indicates likely precocious puberty
- Testes should be palpated to assess if size is pre-pubertal or pubertal volume (>3 ml) and for lumps
- Testicular volume assessed using orchidometer
- Unilateral enlargement suggests serious pathology
- Pre-pubertal testes volume, associated with the development of pubic hair and penile growth suggests GIPP
- Increase in testes volume, along with other features of puberty, suggests GDPP

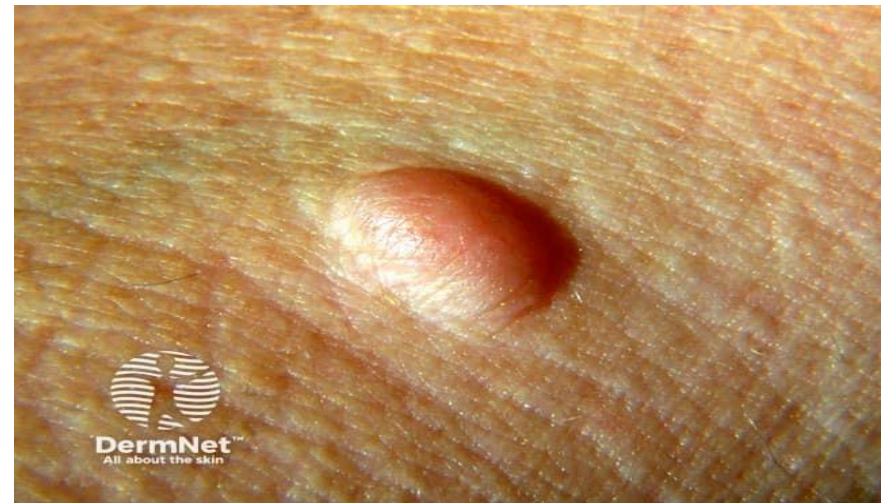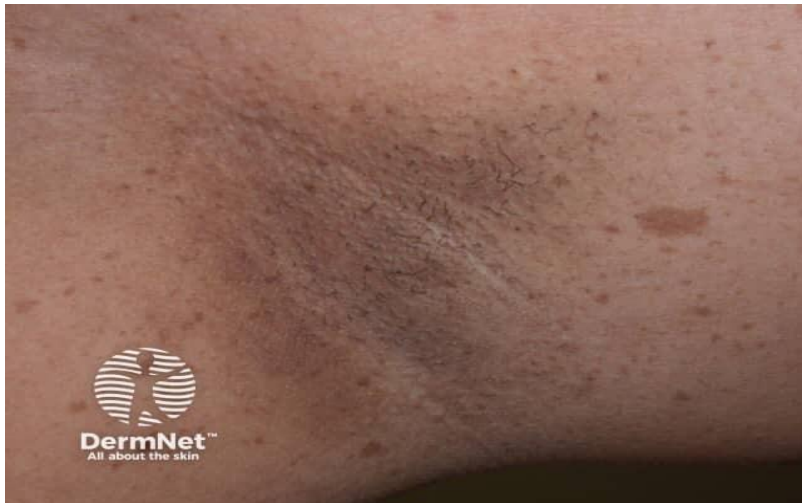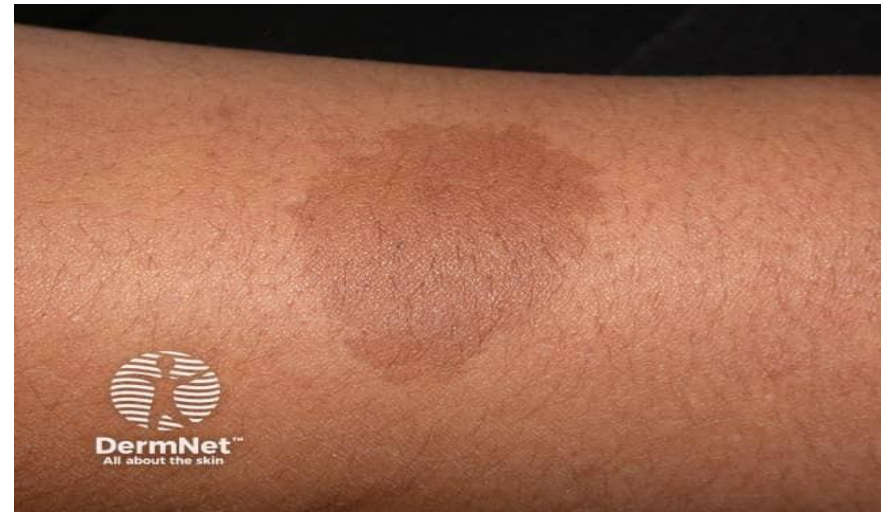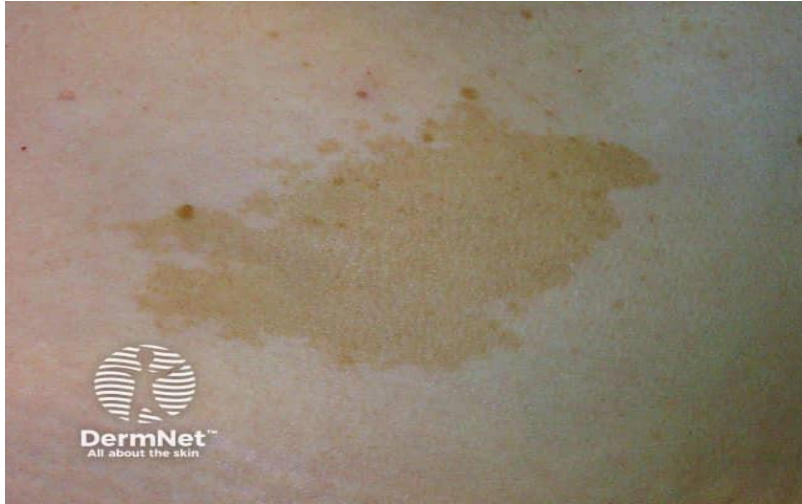# Examination - Girls

- Before 2 years of age, isolated thelarche is common and rarely pathological
- Pubarche in the absence of thelarche may suggest inappropriate androgenic activation - adrenal disorder
- Lipomastia without development of true glandular breast tissue is common, particularly in obese
- Discriminating between lipomastia and true breast tissue can be challenging - palpation under the areolae should reveal firm glandular tissue if thelarche has begun

# Examination – Also...

- Café au lait spots - Neurofibromatosis type 1 (regular edges) and McCune-Albright syndrome (irregular edges)
- Facial asymmetry and hyperostosis of the base of the skull - polyostotic fibrous dysplasia - McCune-Albright syndrome
- Neurofibromas, axillary freckling - Neurofibromatosis type 1
- Lisch nodules - Neurofibromatosis type 1

# Examination – Also...



Demonstrate The Investigations  
That Are Needed to Aid  
Diagnosis of Precocious Puberty

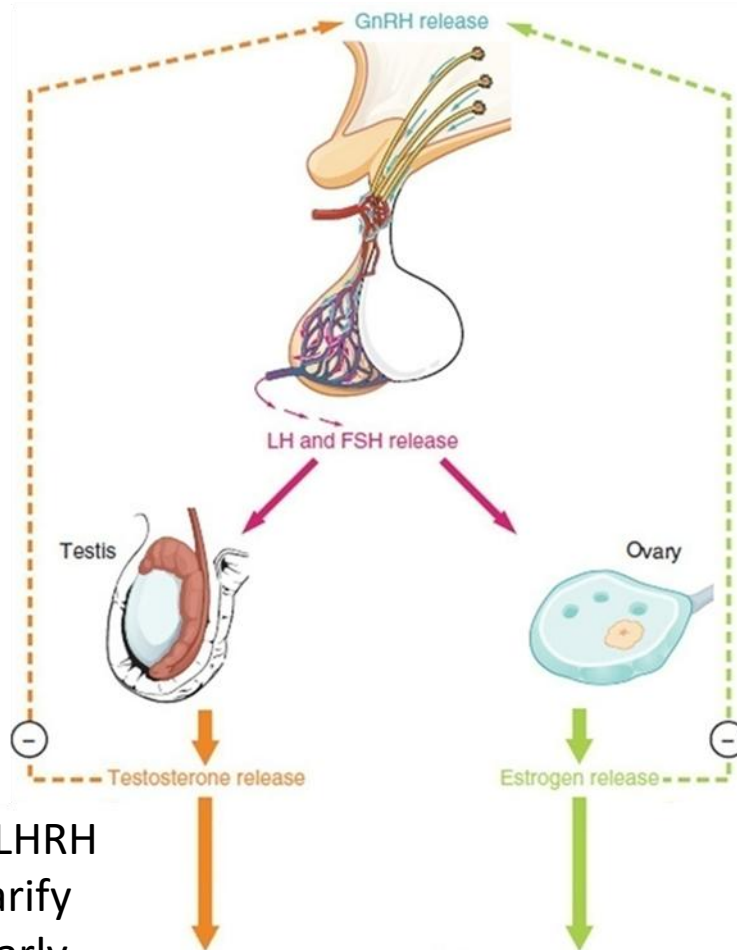
# Investigations

Problem here



— Gonadotropin  
— Dependent PP

Elevated gonadotropin levels  
— Raised LH+FSH



If LH is low then need LHRH stimulation test to clarify  
LH can be low as in early stages of puberty when HPG axis activity is not day+night

LHRH Stimulation Test  
Pre-pubertal children should have no/limited response of LH or FSH to LHRH.

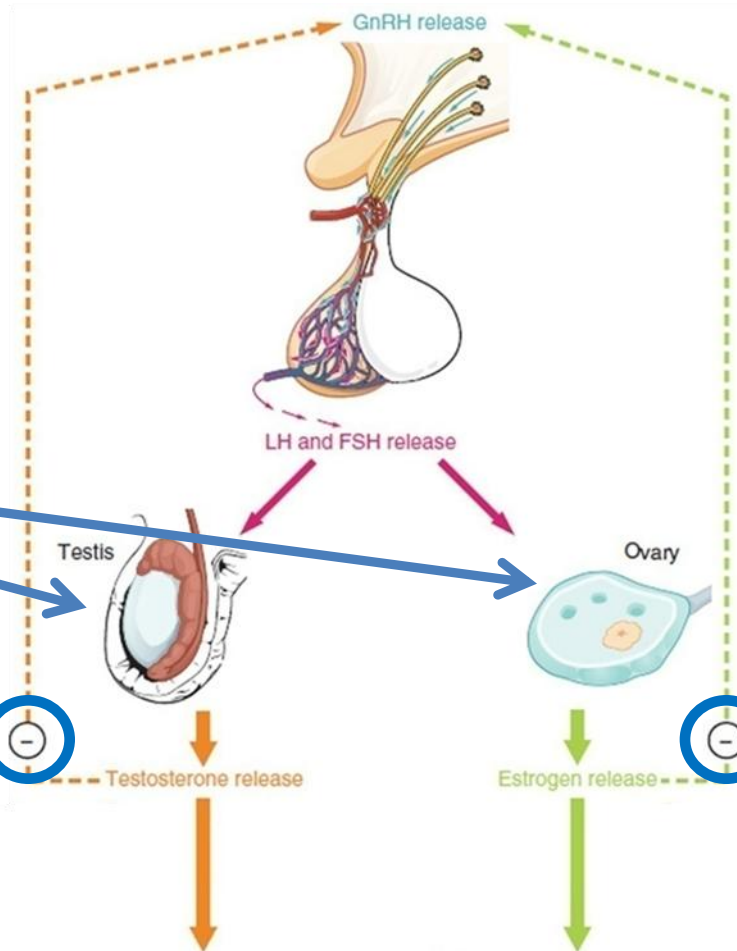
If sex steroids are present (i.e. child undergoing precocious puberty), the pituitary will be "primed" and will therefore respond to LHRH

— Raised LH


— Gonadotropin  
— Dependent PP


— Do MRI Head

# Investigations



Problem here

 Gonadotropin Independent PP


Elevated feedback to hypothalamus  
 Low LH+FSH

## LHRH Stimulation Test

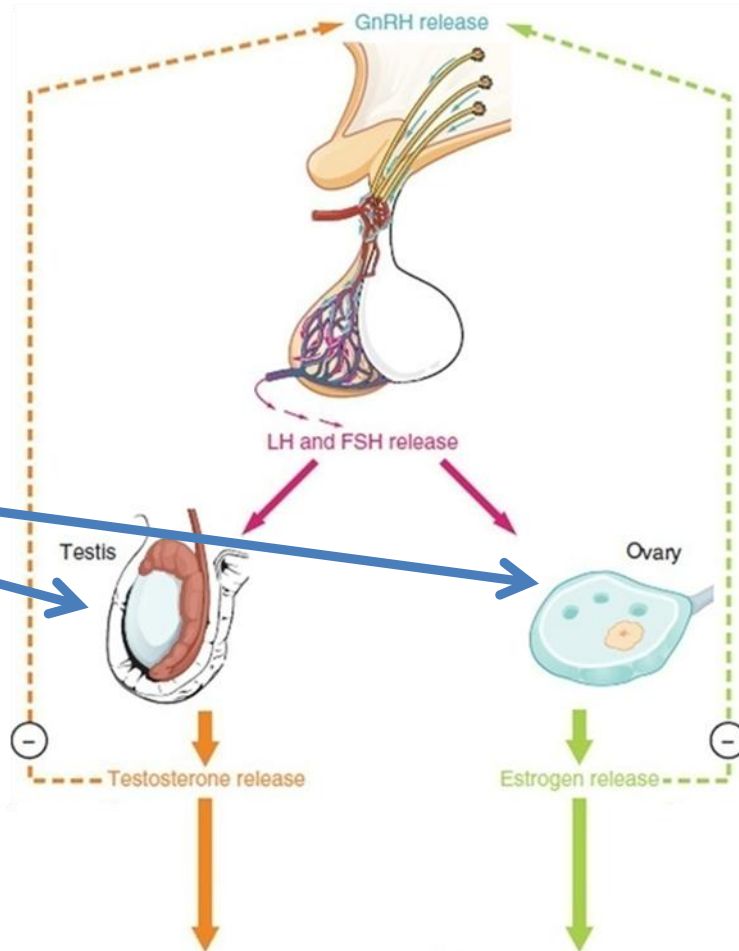
Pre-pubertal children should have no/limited response of LH or FSH to LHRH.

If sex steroids are present (i.e. child undergoing precocious puberty), the pituitary will be "primed" and will therefore respond to LHRH

 Low LH

 Gonadotropin Independent PP

# Investigations



Problem here

— Gonadotropin Independent PP

Investigations to Consider  
Abdo/pelvic/genital imaging  
Genetic tests



Differential Diagnosis  
Tumour (ovary, testis)  
McCune-Albright Syndrome  
Testotoxicosis (LH receptor mutation)

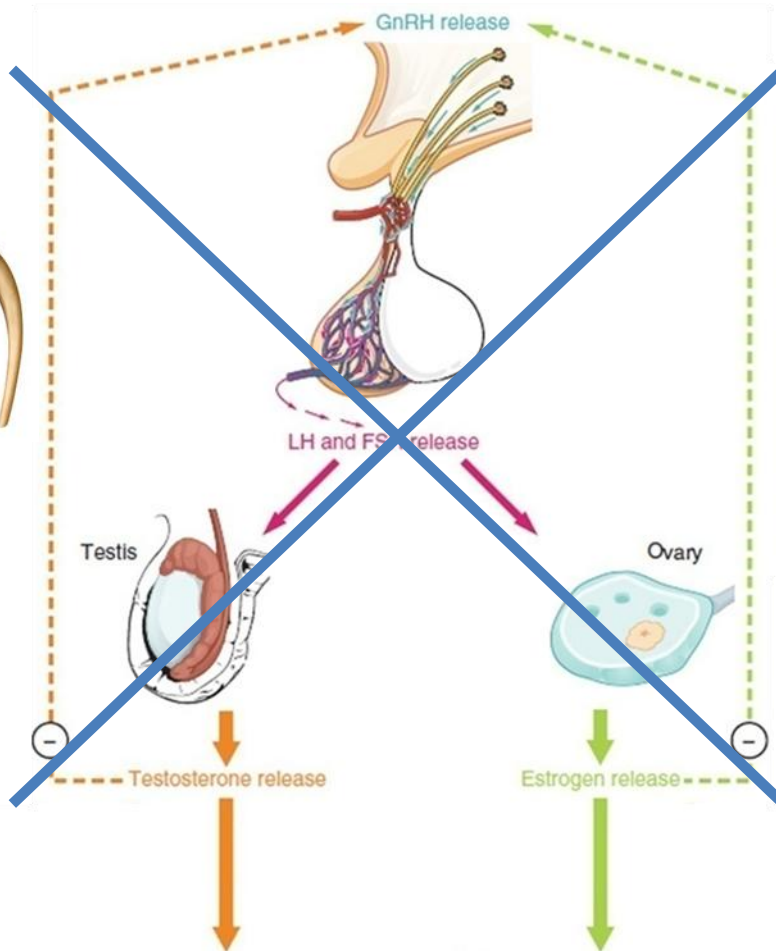
# Investigations

But....

Problem here

Adrenal Problem

 Gonadotropin  
 Independent PP



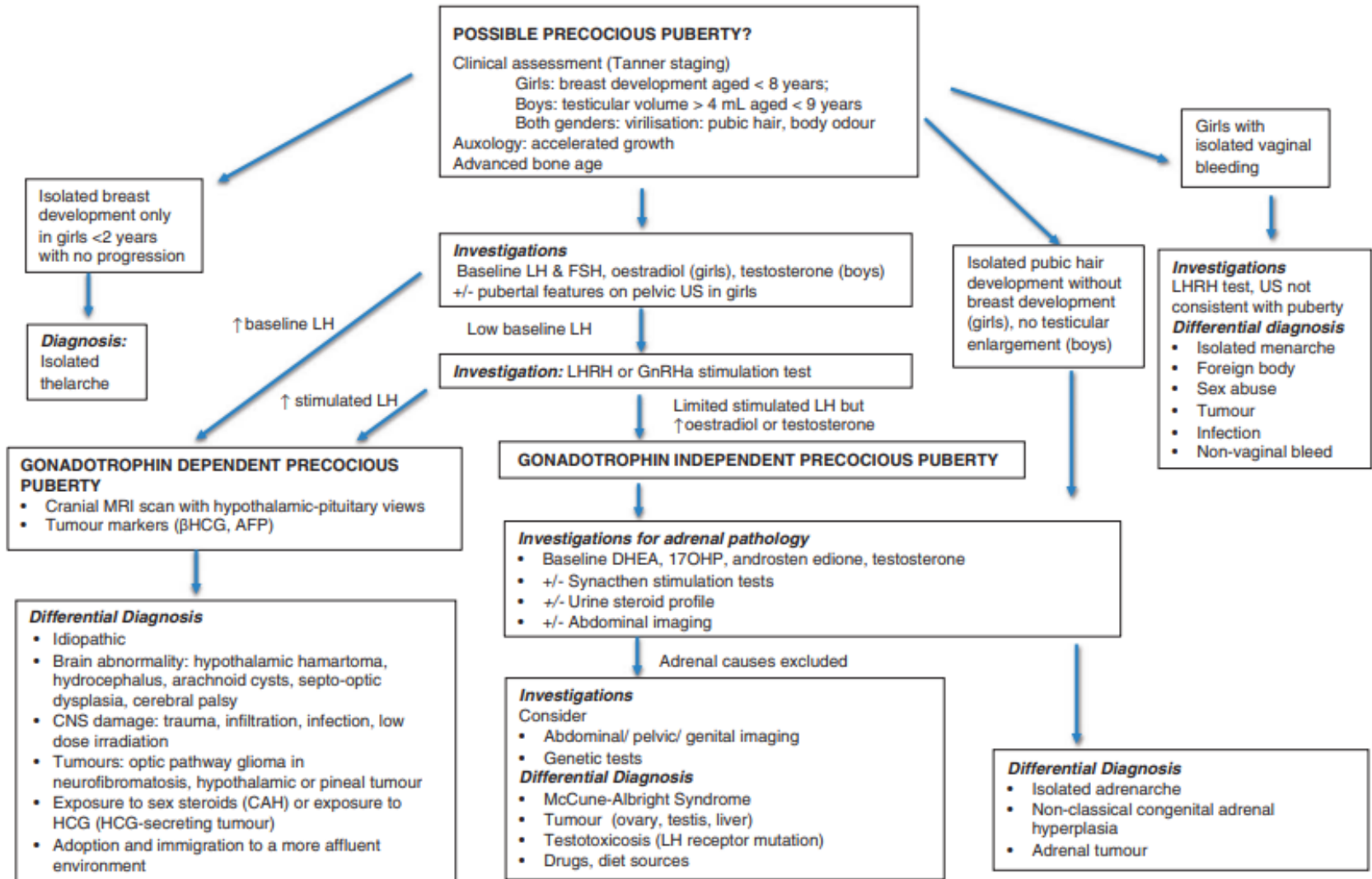
## Investigations for Adrenal Causes

Baseline: DHEA, 17OHP, Testosterone  
 Synacthen stimulation tests  
 Urine steroid profile  
 Abdo imaging

## Differential Diagnosis

Isolated adrenarache  
 Non-classical CAH  
 Adrenal tumour

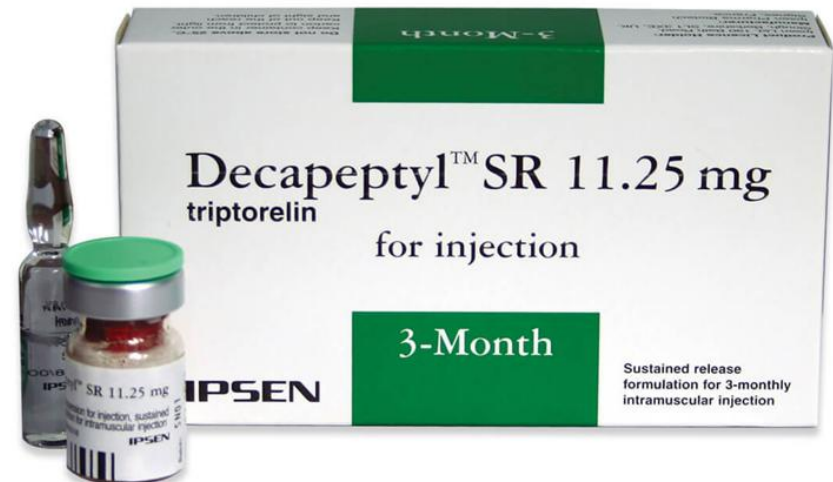# Investigations



Key: DHEA- dehydroepiandrosterone sulphate , 17OHP- 17-hydroxyprogesterone, FSH - follicle stimulating hormone, LH - luteinising hormone, US - ultrasound

# Treatment

- GDPP is usually straightforward with gonadotropin-releasing hormone agonists – e.g. Triptorelin IM injection three monthly
- Therapy with GnRH analogues, in order to prevent premature fusion of epiphyses and preserve adult height potential
- These drugs suppress gonadotropin secretion through a desensitization and downregulation of GnRH receptors, leading to reduction of gonadal steroids to prepubertal levels
- Treatment stopped once an acceptable age of puberty reached



# Treatment

- For parents and children worried about early onset of periods, it may be reassuring to know that in children with untreated precocious puberty, menarche has been observed to commence after a mean of 4.5 years. This corresponds to a mean age of 11.9 years at menarche, which is only slightly earlier than that of a population cohort (12.3 years).
- Unless red flags are present, girls over 6 and their parents can be advised that precocious puberty is very common, usually does not represent any sinister cause, and that in most cases is slow to progress

# When Do I Refer?

## **Box 3: Red flags (urgent referral or discussion with specialist suggested)**

- Precocious puberty in boys (penile growth and/or testicular enlargement before age 9)
- Clitoromegaly
- Growth centiles—steep upward trend (increasing across one or more centile spaces—eg, below 50th to above 75th centile, in 3-6 months) could be indicative of GDPP resulting from cranial pathology
- Menarche before age 8 (consider other causes of vaginal bleeding)
- Progressive breast enlargement before age 8, over a period of 4-6 months, along with upward crossing of height centile(s)
- Pubertal development alongside new onset polydipsia/polyuria, which could manifest as bed wetting (may indicate possible pituitary/hypothalamic pathology)
- Presence of headaches, visual disturbances, or signs of raised intracranial pressure (indicating intracranial pathology)
- Unilateral café au lait macules (present at/shortly after birth), facial asymmetry, or signs of hyperthyroidism or Cushing's syndrome (indicative of McCune-Albright syndrome)
- Presence of pubic hair with or without breast development in infancy
- History of central nervous system disorders or injury such as previous meningitis, central nervous system trauma, cranial irradiation, hypoxic-ischaemic injury, or neurofibromatosis

Any Questions...?

# Aims/Objectives

- By the end of this session you can now ...
- Describe what Precocious Puberty is
- Explain the physiology of normal onset of puberty and it's clinical picture
- Recognize the differences between the two forms of Precocious Puberty
- Categorize the different causes Precocious Puberty
- Discuss the important aspects of the history and examination of a child with Precocious Puberty
- Demonstrate the investigations that are needed to aid diagnosis of Precocious Puberty

# Premature Adrenarche

- The key features of premature adrenarche include:
  - Appearance of pubic and/or underarm hair in girls younger than 8 years or boys younger than 9 year
  - Adult-type underarm odor, often requiring use of deodorant
  - Absence of breast development in girls or of genital enlargement in boys (which, if present, often points to the diagnosis of true precocious puberty)
- A small percentage of children with premature adrenarche may be found to mild congenital adrenal hyperplasia (CAH)
- Urine Steroid Profile will exclude this

# Premature Adrenarche

- In general, no health problems are directly caused by premature adrenarche
- Girls with premature adrenarche may have periods a few months earlier than they would have otherwise
- Some girls with premature adrenarche seem to have an increased risk of developing a disorder called polycystic ovary syndrome (PCOS) in their teenaged years
- There is no treatment that will cause the pubic and/or underarm hair to disappear. Medications that slow down the progression of true precocious puberty have no effect on the adrenal hormones made in children with premature adrenarche

# References

- Bradley 2020. Precocious puberty. The BMJ 2020. 368:l6597.
- Bajpai 2011. Contemporary issues in precocious puberty. Indian Journal of Endocrinology and Metabolism 2011. Vol 15 (7):172-179.
- <https://www.ncbi.nlm.nih.gov/books/NBK470280/>
- Chiocca 2012. Central Precocious Puberty: Treatment with Triptorelin 11.25 mg. The Scientific World Journal Volume 2012, Article ID 583751, 6 page.
- Prentice 2021. Fifteen-minute consultation: Clinical pubertal assessment. Arch Dis Child Educ Pract Ed 2022;107:253–256.
- Wei 2017. The investigations of children and adolescents with abnormalities of pubertal timing. Annals of Clinical Biochemistry 2017. Vol 54 (1):20-32.
- <https://healthjade.com/precocious-puberty/>

# References

- <https://dermnetnz.org/topics/cafe-au-lait-macule>
- <https://dermnetnz.org/topics/neurofibromatosis>
- American Academy of Paediatrics 2018. Paediatric Endocrinology Fact Sheet, Premature Adrenarche: A Guide for Families